

2nd EDITION

PRACTICAL TRAINING

HUMAN PAPILLOMAVIRUS

PRACTICAL CASES

MODULE 3. HPV DIAGNOSIS

Dr. Damián Dexeus

Dr. Javier Cortés





© Saned 2020

All rights reserved. No part of this publication may be reproduced, stored in a retrieval system or transmitted in any form or by any means, electronic, mechanical, photocopying, recording or otherwise, without prior permission of the Editors.

Sanidad y Ediciones, S.L.
gruposaned@gruposaned.com

Poeta Joan Maragall, 60, 1^a. Planta. 28020 Madrid (Spain).
Tel.: +34 91 749 95 00 - Fax: +34 91 749 95 01

Carrer Frederic Mompou, 4A, 2^o, 2^a. 08960 Sant Just Desvern. Barcelona (Spain).
Tel.: +34 93 320 93 30 - Fax: +34 93 473 75 41

INDEX



| | |
|----------------------------------------------|-----------|
| AUTHORS..... | 1 |
| INTRODUCTION..... | 2 |
| OBJECTIVES..... | 3 |
| 1. DETERMINATION OF HPV DNA/RNA | 4 |
| 2. COMPLEMENTARY METHODS | 7 |
| 2.1. Cytology | 7 |
| 2.2. Colposcopy..... | 8 |
| 2.3. Biopsy..... | 10 |
| 3. CONCLUSIONS | 11 |
| BIBLIOGRAPHY..... | 12 |



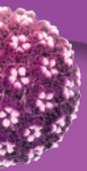
AUTHORS

Dr. Damián Dexeus

Medical Director. Women's Health Institute. Barcelona.

Dr. Javier Cortés

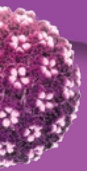
Former President of the Spanish Association of Cervical Pathology and Colposcopy (AEPCC)
Palma.





INTRODUCTION

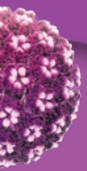
Papanicolaou's cervical-vaginal cytology (the Pap smear) has become a fundamental tool in cervical cancer screening programs. This tool has allowed greater understanding of pre-invasive and invasive cervical lesion histology, and, above all, the role played by human papillomavirus (HPV) in oncogenic phenomena. This knowledge has enabled new strategies for the diagnosis and treatment of pre-invasive and invasive cervical lesions.





OBJECTIVES

The aim of this module is to understand HPV detection techniques and various complementary methods used to diagnose and manage pre-invasive cervical lesions.



1. DETERMINATION OF HPV DNA/RNA

Over the past few years, multiple HPV detection methods have been developed for screening and in patients with known cytological changes, particularly ASC-US (Atypical Squamous Cells of Undetermined Significance).

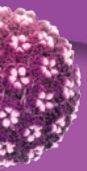
Serology is not a particularly reliable method for differentiating recent infections from older ones. This is because HPV does not grow in conventional cell cultures and the antibodies produced as an immune response to the capsid antigens are detectable for years. For this reason, *molecular* detection techniques are more efficacious.

HPV detection methods work by detecting either DNA, RNA, or proteins synthesized from the RNA^{1,2}. For DNA and RNA detection, there are two major methodologies. Amplification methods increase the amount of nucleic acid during the process (PCR and Real-Time PCR), while methods without amplification (e.g. hybridization) may also be used.

Papillomavirus detection in cervical mucus does not automatically imply *infection* in the strict sense. The *integration* of the virus into the cellular genome is a necessary condition for infection and persistence. The instability of the viral genome in the E2 region and subsequent expression of the E6 and E7 oncogenes are responsible for the cellular effects that cause the cell's malignant transformation. mRNA detection of E6 and E7 oncogenes using PCR or Fluorescent In Situ Hybridization (FISH) objectively determines viral-cellular integration.

Currently, there are more than 125 commercial techniques on the market for HPV detection, with more than 84 variants of these. Though HPV detection principles are familiar today, for the proper interpretation of results and to know the limitations of these tests, it is important to understand the mechanisms on which these platforms are based. In general, four types can be distinguished:

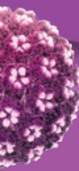1. DNA detection techniques. After the extraction of nucleic acids, these techniques detect the presence of DNA from the capsid region or the HPV E6 oncogene. These can be "*consensus*" *techniques* (detecting all the genotypes belonging to groups 1 and 2A) (Table 1) or *full genotyping* (detecting and identifying all HPV serotypes from groups 1 and 2A and most of group 2B). An advantage of consensus techniques is that they limit themselves to detecting a smaller group of high-risk genotypes that are more important for cervical cancer screening. Full genotyping techniques are very useful for conducting epidemiological studies and stratifying the risk by reporting the specific genotype. They can also be used in the case of clinical lesions where the most common genotypes are not detected.



2. **RNA detection techniques.** After the extraction of nucleic acids, these techniques detect the presence of mRNA for HPV E6/E7 oncogenes. These may be “consensus” techniques or techniques for genotyping 5 genotypes belonging to group 1 (HPV 16, 18, 31, 33, 45).
3. **In situ hybridization techniques.** The clinical sensitivity and specificity of these techniques are insufficient.
4. **Serological techniques.** Although serology is used in vaccine efficacy and epidemiological studies, it cannot be used for routine diagnostics due to its low sensitivity and specificity.

| GENUS | HPV GENOTYPES | COMMENTS |
|----------------------------|--------------------------------------------|-----------------------------------------------------------------------------------|
| Alphapapillomavirus | | |
| 1 | 16 | Highly oncogenic, causes cancer in several anatomical locations |
| 1 | 18, 31, 33, 35, 39, 45, 51, 52, 56, 58, 59 | Sufficient evidence of cervical cancer |
| 2A | 68 | Strong evidence of cervical cancer |
| 2B | 26, 53, 66, 67, 70, 73, 82 | Limited evidence of cervical cancer |
| 2B | 30, 34, 69, 85, 97 | Phylogenetically analogous to genotypes with sufficient or limited evidence |
| 3 | 6, 11 | Low-risk genotype |
| Betapapillomavirus | | |
| 2B | 5, 8 | Limited evidence for skin cancer in patients with epidermodysplasia verruciformis |
| 3 | Other types | |

Despite the existence of the tremendous number of tests available on the market, only a few have been approved by the Food and Drug Administration (FDA) (Table 2)³ for their use in population-wide screening. It is not viable to conduct randomized longitudinal trials with all the HPV detection tests on the market. In 2009, an international committee of experts⁴ proposed that any test must be at least as precise and reproducible as the techniques used in the gold standard or reference method assays (PCR with GP5+/GP6+ primers and hybrid capture) in order to be used in primary screening for cervical cancer in women 30 years of age or older. Specifically, these are validation criteria based on the sensitivity and specificity for the detection of cervical lesions.



For a technique to be validated, it must demonstrate sensitivity and specificity relative to the *gold standard* of ϵ 0.90 and ϵ 0.98, respectively.

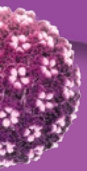
Table 2. Tests for HPV detection approved by the Food and Drug Administration for use in population screening.

- Hybrid Capture 2 (HC2) HPV DNA Test (Qiagen Inc., Gaithersburg, Maryland; United States) US FDA (2003).
- Cervista HPV HR Test (Hologic, Madison, Wisconsin, United States) US FDA (2009).
- Cobas* 4800 HPV Test (Roche Molecular Systems Inc., Alameda, California, United States) US FDA (2011).
- APTIMA HPV Test (Gen-Probe Inc., San Diego, California, United States) US FDA (2011)
- BD Onclarity* (Becton Dickinson) US FDA (2018)

*Cobas and BD Onclarity are the only tests specifically approved by the FDA for cervical cancer screening.

**CLART@HPV4S⁵.

HPV tests should be used for population-wide screening in women between ages 30 and 65. They should not be used in women under the age of 30 because, despite the high prevalence of HPV, the majority of infections will clear spontaneously within two years^{6,7}.



2. COMPLEMENTARY METHODS

2.1. Cytology

Papanicolaou's cytology (the smear described in 1941) detects premalignant lesions and is therefore the primary means of early cervical cancer diagnosis⁸. Used in countries with population-wide screening programs, it has been responsible for a decrease in cervical carcinoma.

The success of cytological screening programs lies in attaining broad coverage (equal or greater than 75% of the population) and ensuring the quality of the cytology.

Cervical cytology is based on the morphological study of the cells obtained by endocervical and ectocervical brushing. Those cells infected with HPV present a series of morphological changes that can be identified by cytopathologists. This morphological analysis helps the clinician decide if a woman presents a risk of suffering cancer in the coming years or not, and thereby helps to adjust the patient's monitoring protocol.

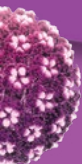
The main problem with cytology is its variable and relatively low sensitivity, which is estimated at 70-75% for the detection of CIN2 positivity under the best quality conditions⁹⁻¹². This relatively low sensitivity is due to the variation in the material obtained during sampling, the quality of cytological extent, as well as the capacity for detection and interpretation by professionals. Therefore, it is essential to have a quality sample that has been obtained under appropriate technical conditions.

Quality, well-organized population screening at appropriate intervals can limit these drawbacks. However, there is an efficiency trade-off if excessively reducing the testing intervals.

The specificity of cytology in detecting CIN2 positivity is high (around 95%)¹³⁻¹⁶.

Among the different strategies that have been proposed to improve the quality of cytology are monolayer, thin-layer, or liquid-based cytology. The material obtained is preserved immediately following its extraction in a liquid medium that allows for storage and transport. These strategies reduce the number of cases that cannot be diagnosed due to inadequate material, and reduce microscope read time²⁷.

The greatest added value of liquid cytology is most likely that the remaining material (not all of it is used for the cytological study) allows performance of additional techniques like HPV determination or immunocytochemical techniques like p16/KI67 detection.



When cytology is used in health care, it should be implemented to increase the sensitivity of diagnosis. The combination of simultaneous cytology and colposcopy obtains a negative predictive value of practically 100% in detecting CIN2 positivity or invasive carcinoma²⁸⁻³¹.

2.2. Colposcopy

Colposcopy is a technique described by Hinselmann in 1925, based on the magnified exploration of the epithelia of the cervix, vagina and vulva.

Its primary objective is the diagnosis of pre-invasive and invasive lesions of the lower genital tract.

Histology is the basis for colposcopic images. It is therefore essential to know both the distinct histological profiles of the cervix as well as their etiopathogenic mechanisms.

Colposcopy is a dynamic technique that allows us to differentiate the two fundamental phases of the natural history of cervical neoplasia. The first phase is intraepithelial, identifying predominantly aceto-white lesions. These lesions reflect epithelial changes that hinder or impede light's passage toward the stroma. The second is the initial invasive phase, in which irregular vessels and neovessels are identified that appear as a result of the release of angiogenic factors by the tumor cells themselves.

Colposcopy is very sensitive in the detection of lesions that are precursors to cervical cancer. However, it is not very specific, as the abnormal colposcopic images are not always the reflection of a premalignant intraepithelial lesion. Colposcopy allows us to classify the images based on the architectural pattern of the epithelium, such that different grades exist for an abnormal image. The current colposcopic terminology is the one ratified by the Nomenclature Committee of the International Federation for Cervical Pathology and Colposcopy (IFCPC) at the 2011 Rio World Congress (Table 3)³².

Colposcopy offers heightened sensitivity in differentiating normal from pathological epithelia. It has greater specificity in distinguishing LSIL from HSIL than for differentiating normal from abnormal. All of this confirms the validity of the current colposcopic classification, which distinguishes between grade 2 changes, belonging to HSIL lesions and cancer, and grade 1 lesions that are LSIL and normal.

Colposcopically-directed biopsy helps confirm the diagnosis before undertaking definitive treatment. It is considered the gold standard in diagnosing pre-invasive or invasive cervical lesions.

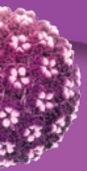


Table 3. 2011 International Federation for Cervical Pathology and Colposcopy (IFCPC) colposcopic terminology of the cervix.

| | |
|--------------------------------------|----------------------------------------------------------------------------------------------------------------------------------------------------------------------------------------------------------------------------------------------------------------------------------------------------------------------------------------------------------------------------------------------|
| General assessment | <ul style="list-style-type: none"> • Adequate/inadequate for the reason... (i.e.: cervix obscured by inflammation, bleeding, scar). • Squamo-columnar Junction visibility: completely visible, partially visible, not visible. <p>Transformation zone types: 1, 2, 3.</p> |
| Normal colposcopic findings | <p>Original squamous epithelium:</p> <ul style="list-style-type: none"> • Mature. • Atrophic. <p>Columnar epithelium:</p> <ul style="list-style-type: none"> • Ectopy. <p>Metaplastic squamous epithelium:</p> <ul style="list-style-type: none"> • Nabothian cysts. • Crypt (gland) openings. <p>Deciduous in pregnancy.</p> |
| Abnormal colposcopic findings | <p style="text-align: right; color: white; font-weight: normal;">General principles</p> <ul style="list-style-type: none"> • Location of the lesion: inside or outside the T-zone, location of the lesion by clock position. • Size of the lesion: number of cervical quadrants the lesion covers, size of the lesion in percentage of cervix. |
| Grade 1 (Minor) | <ul style="list-style-type: none"> • Thin aceto-white epithelium. • Irregular, geographic border. • Fine mosaic. • Fine punctuation. |
| Grade 2 (Major) | <ul style="list-style-type: none"> • Dense aceto-white epithelium. • Rapid appearance of acetowhitening. • Cuffed crypt (gland) openings. • Coarse mosaic. • Coarse punctuation. • Sharp border. • Inner border sign. • Ridge sign. |
| Non-specific | <ul style="list-style-type: none"> • Leukoplakia (keratosis, hyperkeratosis). • Erosion. • Lugol's staining (Schiller's test): stained/non-stained. |
| Suspicious for invasion | <ul style="list-style-type: none"> • Atypical vessels. • Additional signs: fragile vessels, irregular surface, exophytic lesion, necrosis, ulceration (necrotic), tumor/gross neoplasm. |

(Continued on next page)

Table 3. 2011 International Federation for Cervical Pathology and Colposcopy (IFCPC) colposcopic terminology of the cervix. (*Continuation*)

| Miscellaneous findings | |
|--------------------------------------------------------------------------------------------------------------------------------|-------------------------------------------------------------------------------------------------------------------------------------------------------------------------------------------------------|
| <ul style="list-style-type: none">• Congenital transformation zone.• Condyloma.• Inflammation. | <ul style="list-style-type: none">• Polyp (ectocervical/endocervical).• Stenosis.• Congenital anomaly.• Post treatment consequence.• Endometriosis. |

2.3. Biopsy

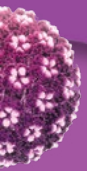
The final diagnosis of premalignant and malignant lesions of the cervix is based on the histopathological study of biopsies. These include both colposcopically-directed biopsies as well as surgical specimens from conization and hysterectomy.

Screening techniques (cytology, molecular HPV detection techniques and colposcopy) use histological diagnosis as a reference standard for comparison. It is easy to understand the importance of ensuring precision and excellence in histological diagnosis.

The first determining factor is the colposcopist themselves. They must ensure that the tissue sample collected is representative of the lesion observed and that this includes both the surface epithelium and the underlying stroma. Some studies have shown that taking an increased number of biopsies during the colposcopic exam translates into a significant increase in the high-grade intraepithelial lesions diagnosed^{33,34}.

Correct and complete identification of the sample helps the pathologist make an appropriate evaluation. Excisional (cone) biopsies should be labeled with identifying points for proper spatial orientation of the specimen.

Sample processing in a laboratory regulated by a quality management system is essential for the pathologist to appropriately read and interpret the sample.

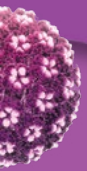




3. CONCLUSIONS

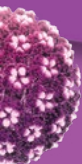
HPV detection tests have become first-line tests in cervical cancer screening programs. Using a validated test ensures results can reliably guide follow-on actions. Additionally, knowing the test characteristics, advantages, and limitations is essential for appropriate use.

Cytology, colposcopy and biopsy continue to be fundamental tools in both diagnosis and management of pre-invasive and invasive cervical lesions.

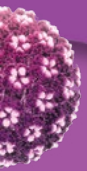


BIBLIOGRAPHY

1. Lacruz C. Citología de las lesiones intraepiteliales escamosas [Cytology of squamous intraepithelial lesions]. In: Lacruz C, Fariña J, eds. Citología ginecológica. De Papanicolaou a Bethesda [Gynecological cytology: From Papanicolaou to Bethesda]. Madrid: Editorial complutense; 2003. p. 65-87.
2. Lacruz C, Vilaplana E. Citología endocervical [Endocervical cytology]. In: Lacruz C, Fariña J, eds. Citología ginecológica. De Papanicolaou a Bethesda [Gynecological cytology: From Papanicolaou to Bethesda]. Madrid: Editorial complutense; 2003. p. 115-36.
3. Bouvard V, Baan R, Straif K, Grosse Y, Secretan B, El Ghissassi F, et al. WHO International Agency for Research on Cancer Monograph Working Group. A review of human carcinogens--Part B: biological agents. *Lancet Oncol.* 2009;10:321-22.
4. Meijer CJ, Berkhof J, Castle PE. Guidelines for human papillomavirus DNA test requirements for primary cervical cancer screening in women 30 years and older. *Int J Cancer.* 2009;124:516-20.
5. Ejegold DM, Lagheden C, Bhatia R, Pedersen H, Alcañiz Boada E, Sundström K, Cortés J, Bosch FX, Cuscheri K, Dillner J, Bonde JH.: Clinical validation of full genotyping CLART® HPV4S assay on SurePath and ThinPrep collected Screening samples according to the International Guidelines for Human Papillomavirus Test Requirements for Cervical Screening. *J Clin Virol*, in press.
6. Torné A, del Pino M, Cusidó M, Alameda F, Andia D, Castellsagué X, et al. Guía de cribado del cáncer de cuello de útero en España [Spanish Cervical Cancer Screening Guidelines]; 2014.
7. Bulkmands NWJ, Berkhof J, Bulk S, Bleeker MCG, van Kemenade FJ, Rozendaal L, et al. *British Journal of Cancer.* 2007;96:1419-24.
8. Papanicolaou GN. *Am J Obstet Gynecol* 1941;2(42).
9. Arbyn M, Ronci G, Anttila A, Meijer CJ, Poljak M, Ogilvie G, et al. Evidence regarding human papillomavirus testing in secondary prevention of cervical cancer. *Vaccine.* 2012;30(5):88-99.
10. Results of a randomized trial on the management of cytology interpretations of atypical squamous cells of undetermined significance. *Am J Obstet Gynecol.* 2003;188:1383-92.
11. Castle PE, Bulten J, Confortini M, Klinkhamer P, Pellegrini A, Siebers AG, et al. Age-specific patterns of unsatisfactory results for conventional Pap smears and liquid- based cytology: data from two randomised clinical trials. *BJOG.*2010;117:1067-73.



12. Chen HC, Schiffman M, Lin CY, Pan MH, You SL, Chuang LC, et al. Persistence of type-specific human papillomavirus infection and increased long-term risk of cervical cancer. *J Natl Cancer Inst.* 2011;103:1387-96.
13. Puig-Tintore LM. Estudio Cooperativo Español [Spanish Cooperative Study]. Proceedings of the IV Reunión de la Sección de Prevención del Cáncer de la SEGO [Fourth Meeting of the Cancer Prevention Section of the Spanish Society of Gynecology and Obstetrics (SEGO)]. Valladolid, 1982.
14. Fahey MT. Meta-analysis of Pap-Test accuracy. *Am J Epidemiol.* 1995;141:680-9.
15. Nanda K. Accuracy of the Papanicolaou test in screening and follow-up of cervical cytologic abnormalities: A Systematic review. *Ann Intern Med* 2000;132:810-19.
16. Cuzick J. Management of women who test positive for high risk types of human papillomavirus: The HART study. *Lancet* 2003;362:1871-76.
17. Davey E. Effect of study design and quality on unsatisfactory rates, cytology classifications and accuracy in liquid-based versus conventional cervical cytology: A systematic review. *Lancet* 2006;376:122-32.
18. Akamatsu S, Kodama, Himeji Y, Ikuta N, Shimagaki N. A comparison of liquid-based cytology with conventional cytology in cervical cancer screening. *Acta Cytol.* 2012;56:370-4.
19. Arbyn M, Bergeron C, Klinkhamer P, Martin-Hirsch P, Siebers AG, Bulten J. Liquid compared with conventional cervical cytology: a systematic review and meta-analysis. *Obstet Gynecol.* 2008;111:167-77.
20. Davey E, D'Assuncao J, Irwig L, Macaskill P, Chan SF, Richards A, et al. Accuracy of reading liquid based cytology slides using the ThinPrep Imager compared with conventional cytology: prospective study. *BMJ.* 2007;335:31.
21. De Bekker-Grob EW, de Klok IM, Bulten J, van Rosmalen J, Vedder JE, Arbyn M, et al. Liquid-based cytology using Thin Prep technology: weighing the pros and cons in a cost-effectiveness analysis. *Cancer Causes Control.* 2012;23:1323-31.
22. Hutchinson ML, Zahniser DJ, Sherman ME, Herrero R, Alfaro M, Bratti MC, et al. Utility of liquid-based cytology for cervical carcinoma screening: results of a population-based study conducted in a region of Costa Rica with a high incidence of cervical carcinoma. *Cancer.* 1999;87:48-55.
23. Monsonego J, Autillo-Touati A, Bergeron C, Dachez R, Liaras J, Saurel J, et al. Liquid-based cytology for primary cervical cancer screening: a multi-centre study. *Br J Cancer.* 2001;84:360-6.





24. Pan QJ, Hu SY, Zhang X, Ci PW, Zhang WH, Guo HG, et al. Pooled analysis of the performance of liquid-based cytology in population-based cervical cancer screening studies in China. *Cancer Cytopathol.* 2013;121:473-82.
25. Sigurdsson K. Is a liquid-based cytology more sensitive than a conventional Pap smear? *Cytopathology.* 2013;24:254-63.
26. Whitlock EP, Vesco KK, Eder M, Lin JS, Senger CA, Burda BU. Liquid-based cytology and human papillomavirus testing to screen for cervical cancer: a systematic review for the U.S. Preventive Task Force. *Ann Intern Med.* 2011;155:687-97.
27. Wright TC Jr., Stoler MH, Behrens CM, Sharma A, Sharma K, Apple R. Interlaboratory variation in the performance of liquid-based cytology: insights from the ATHENA trial. *Int J Cancer.* 2014;134:1835-43.
28. Carrera JM, Dexeus S, Coupez F. *Tratado y Atlas de Colposcopia [Treatment and Atlas of Colposcopy]*. Barcelona: Salvat. 1973:228.
29. Puig-Tintoré LM. Detección colposcópica de la neoplasia cervical intraepitelial en mujeres con citología negativa [Colposcopic detection of cervical intraepithelial neoplasia in women with negative cytology]. In: González Merlo J, Iglesias Guiu J, Burzaco I, López de la Osa L. *Avances en Obstetricia y Ginecología [Advances in Obstetrics and Gynecology]*. Barcelona: Salvat. 1984;8:5-12.
30. Dexeus S, Carararch M, Dexeus D. The role of colposcopy in modern gynecology. *Eur J Gynaecol Oncol* 2002;23(4):269-77.
31. Puig-Tintoré LM, Cortés J, Castellsagué X, Torné A, Ordi J, de Sanjosé S, et al. Prevención del cáncer de cuello uterino ante la vacunación frente al virus del papiloma humano [Prevention of cervical cancer by vaccination against human papillomavirus]. *Prog Obstet Ginecol* 2006.
31. Puig-Tintoré LM, Cortés J, Castellsagué X, Torné A, Ordi J, de Sanjosé S, et al. Prevención del cáncer de cuello uterino ante la vacunación frente al virus del papiloma humano [Prevention of cervical cancer by vaccination against human papillomavirus]. *Prog Obstet Ginecol* 2006.
32. Bornstein J, Bentley J, Bösze P, Girardi F, Haefner H, Menton M, et al.: 2011 colposcopic terminology of the International Federation for Cervical Pathology and Colposcopy. *Obstet Gynecol.* 2012; 120: 166-72
33. Gage JC, Hanson VW, Abbey K, Dippery S, Gardner S, Kubota J, et al. Number of cervical biopsies and sensitivity of colposcopy. *Obstet Gynecol.* 2006;108:264-72.
34. Nam K, Chung S, Kwak J, Cha S, Kim J, Jeon S, et al. Random biopsy after colposcopy-directed biopsy improves the diagnosis of cervical intraepithelial neoplasia grade 2 or worse. *J Low Genit Tract Dis.* 201;14:346-51.

